

Modifications in endoscopic practice for pediatric patients

This is one of a series of statements discussing the utilization of GI endoscopy in common clinical situations. The Standards of Practice Committee of the American Society for Gastrointestinal Endoscopy (ASGE) prepared this text. In preparing this guideline, the MEDLINE and PubMed databases were used to search publications through the last 15 years related to pediatric endoscopy by using the keyword “pediatric” and each of the following: “gastrointestinal,” “endoscopy,” “colonoscopy,” “inflammatory bowel disease,” “sedation,” and “anesthesia.” The search was supplemented by accessing the “related articles” feature of PubMed with articles identified in MEDLINE and PubMed as the references. Pertinent studies published in English were reviewed. Studies or reports that described fewer than 10 patients were excluded from analysis if multiple series with more than 10 patients addressing the same issue were available. The resultant quality indicators were adequate for analysis. The reported evidence and recommendations based on reviewed studies were graded on the strength of the supporting evidence (Table 1).

Guidelines for appropriate utilization of endoscopy are based on a critical review of the available data and expert consensus. Further controlled clinical studies may be needed to clarify aspects of this statement, and revision may be necessary as new data appear. Clinical consideration may justify a course of action at variance to these recommendations.

Pediatric endoscopy is largely in the domain of the pediatric gastroenterologist. Occasionally, pediatric surgeons may be trained in endoscopy. Because children are not simply young adults, optimal performance of endoscopy in these patients requires an adequate knowledge and understanding of pediatrics and a thorough understanding of the child’s medical background.¹ In many practice settings, however, adult endoscopists are called upon to provide advanced therapeutic endoscopic services, such as ERCP and EUS, or basic endoscopic services when pediatric gastroenterologists are unavailable. To provide appropriate care for the child in such circumstances, a team approach is required with the pediatrician or the pediatric gastroenterologist and the adult endoscopist.

This document is intended to provide guidance regarding endoscopic practice issues that may differ in children. Because physiologic age is a continuum, this document is not intended to apply to rigidly defined age ranges. Where useful, such as among pediatric subsets, ages will be specified.

INDICATIONS AND CONTRAINDICATIONS

The indications for upper endoscopy in the pediatric age group are similar to those for adult endoscopy^{2,3} and are summarized in Table 2. The endoscopist must be aware of the fact that all infants, many children, and some adolescents cannot verbalize or describe symptoms accurately. Occult signs and symptoms that may prompt an endoscopy in infants and children include failure to thrive, limitation of usual activities, unexplained irritability, and anorexia.

Two other circumstances that occur more commonly in pediatrics and may require an endoscopy are the ingestion of foreign bodies and caustic substances. The protocol for endoscopic evaluation of foreign-body ingestion is well described in a previous guideline.⁴

Caustic substances include alkali (lyes), alkaline batteries, bleaches, and laundry detergents (powders and liquids). Acids are found in toilet-bowl cleaners, metal cleaners, and battery acids.⁵ Poison control center staff can help identify the caustic substance and make recommendations.⁵ History and physical examination findings suggestive of child abuse or neglect require further investigation.⁵

An upper endoscopy is the most useful means for evaluating esophageal, gastric, and duodenal injury because of ingestion of caustic substances.⁵ However, universal performance of EGD in the setting of known or suspected caustic ingestion in asymptomatic patients (absence of drooling, vomiting, stridor, hematemesis, dysphagia, abdominal pain) or without oropharyngeal injury is controversial.^{6,7} It is important to note that there is a lack of correlation between signs and symptoms and degree of esophageal injury.⁵ An endoscopic grading system for severity of caustic ingestion exists (Table 3).⁵ Early endoscopy seems safe and provides important prognostic information.⁸ Use of a grading system also allows for stratification of therapy. Patients with grades 1 and 2a burns generally do well without aggressive therapy,⁵ whereas those with grades 2b and 3 lesions are at risk for

TABLE 1. Grades of recommendation*

Grade of recommendation	Clarity of benefit	Methodologic strength supporting evidence	Implications
1A	Clear	Randomized trials without important limitations	Strong recommendation; can be applied to most clinical settings
1B	Clear	Randomized trials with important limitations (inconsistent results, nonfatal methodologic flaws)	Strong recommendation; likely to apply to most practice settings
1C+	Clear	Overwhelming evidence from observational studies	Strong recommendation; can apply to most practice settings in most situations
1C	Clear	Observational studies	Intermediate-strength recommendation; may change when stronger evidence is available
2A	Unclear	Randomized trials without important limitations	Intermediate-strength recommendation; best action may differ, depending on circumstances or patient or societal values
2B	Unclear	Randomized trials with important limitations (inconsistent results, nonfatal methodologic flaws)	Weak recommendation; alternative approaches may be better under some circumstances
2C	Unclear	Observational studies	Very weak recommendation; alternative approaches likely to be better under some circumstances
3	Unclear	Expert opinion only	Weak recommendation; likely to change as data become available

*Adapted from Guyatt G, Sinclair J, Cook D, et al. Moving from evidence to action. Grading recommendations: a qualitative approach. In: Guyatt G, Rennie D, editors. *Users' guides to the medical literature*. Chicago: AMA Press; 2002. p. 599-608.

complications.^{5,9} In addition, one study compared early bougienage (performed during the first week after ingestion) to late bougienage (after the third week, if strictures had developed) in group 2b and 3 patients. Early bougienage did not prevent strictures, but, in this group, if strictures occurred, they responded more readily to subsequent dilation.¹⁰

Endoscopy is generally not indicated in pediatric patients for evaluation of symptoms or radiologic signs of uncomplicated gastroesophageal reflux (especially gastroesophageal reflux of infancy), uncomplicated functional abdominal pain, isolated pylorospasm, known congenital hypertrophic pyloric stenosis, constipation and encopresis, and exacerbation of previously documented inflammatory bowel disease that is responding to therapy. However, in some cases, a negative endoscopy can serve as reassurance to the patient and family that nothing has been overlooked in the evaluation.¹¹ Outpatient upper endoscopy in children is safe, though it is complicated by a sore throat and hoarseness in up to a third of patients.¹²

The most common indications for pediatric colonoscopy are shown in Table 4. Included among these indications for pediatric patients are surveillance for neoplasia in those patients with hereditary polyposis syndromes¹³ and surveillance for rejection or other complications after organ transplantation.^{14,15} At the time of both upper endoscopy and colonoscopy, routine tissue sampling is

commonly performed because of an inability to adequately assess differences between normal and abnormal mucosa by using endoscopic appearance alone.¹⁶

Advanced procedures such as ERCP and EUS are also performed in children. However, the need for these procedures occurs far less frequently in children than in adults and, consequently, most pediatric gastroenterologists do not have the opportunity during training or in clinical practice to acquire and maintain proficiency in these procedures. Pediatric indications for ERCP are similar to those for adults, though with a much lower incidence of malignant diseases.¹⁷⁻²⁰ Technical success rates for ERCP are high; however, ERCP-related pancreatitis is not uncommon, and the risk and benefits should be carefully reviewed before proceeding.¹⁹ EUS is indicated in pediatric patients for evaluation of upper-GI-tract tumors and pancreatic disorders, characterization of esophageal strictures, and, in selected patients, for the evaluation of eosinophilic esophagitis.²¹⁻²⁴ The use of EUS is also evolving for the assessment of the anal sphincter in children with constipation or continence problems and for evaluation of enteric duplications.^{25,26} Currently, these procedures are often conducted by adult gastroenterologists because of the proficiency reasons previously mentioned.

Wireless capsule endoscopy (WCE) is used in children and appears to be safe and well tolerated.²⁷⁻³⁰ Although similar indications for WCE in adults³¹ generally apply to

TABLE 2. Indications for pediatric upper endoscopy**Diagnostic**

Dysphagia
 Odynophagia
 Intractable or chronic GERD (including surveillance for Barrett's esophagus)
 Vomiting/hematemesis
 Abdominal pain with significant morbidity or signs of organic disease (weight loss, anemia, vomiting, fevers)
 Anorexia
 Weight loss/failure to thrive
 Anemia (unexplained)
 Diarrhea/malabsorption (chronic)
 Hematochezia
 Caustic ingestion

Therapeutic

Foreign-body removal
 Dilation of esophageal and upper-GI strictures
 Esophageal varices eradication
 Upper-GI bleeding control

TABLE 3. Endoscopic grading of caustic injury severity

Grade 0	Normal
Grade 1 (superficial)	Edema and hyperemia of mucosa
Grade 2a (transmucosal)	Hemorrhage; exudate, erosions and blisters, superficial ulcers
Grade 2b	Grade 2a plus deep discrete or circumferential ulceration
Grade 3 (transmural)	Deep ulceration, eschar formation with necrosis, full-thickness injury with and without perforation

TABLE 4. Indications for pediatric colonoscopy**Diagnostic**

Diarrhea (chronic, clinically significant with weight loss, fevers, anemia)
 Hematochezia/melena
 Anemia (unexplained)
 Abdominal pain (clinically significant)
 Polyposis syndrome (diagnosis and surveillance)
 Rejection of intestinal transplant
 Lower-GI-tract lesions seen on imaging studies?
 Failure to thrive/weight loss

Therapeutic

Polypectomy
 Foreign-body removal
 Dilation of strictures
 Lower-GI bleeding control

children, occult GI bleeding due to vascular pathology is much less common in children. In one series, WCE led to a change in management in 18 of 24 patients (75%) and was more sensitive than radiologic and standard endoscopic modalities in the detection of small-bowel Crohn's distribution, a bleeding source, and the presence of polyps.³⁰ Although WCE is approved for children 10 years and older, it has been applied successfully in children as young as 2 years of age.³² For children who cannot swallow, capsule endoscopic placement can be performed.²⁸

PREPROCEDURE PREPARATION

Preparation for endoscopy in pediatric patients requires attention to physiologic issues, as well as emotional and psychosocial aspects of both the patient and the parent or guardian. Some of the anxiety engendered by endoscopy stems from preprocedure elements of intravenous (IV) line placement¹⁷ and separation from parents. A preprocedure health evaluation, including a health history, American Society of Anesthesiologists (ASA) score, medication history, allergy assessment, age, weight, and baseline vital signs, should be obtained. A physical examination, including a focused airway assessment, should be performed. Pre sedation assessment

appears to reduce the complications of deep sedation in children.³³ Informed consent should be obtained from the appropriately designated parent or guardian or the patient, as stipulated by state regulation or statute.³⁴ Provision of optimal age-appropriate information and counseling to the patient and parents aids in procedure tolerance by the child, because parental attitudes and fears are readily conveyed by nonverbal communication. In one study, 60 patients aged 6 to 19 years old were randomized to psychologic preparation versus routine measures before endoscopy.³⁵ Patients in the intervention group were significantly less anxious before and more cooperative during the procedure, exhibited less autonomic stimulation, and required less sedation.

Pediatric patients with presumed normal gastric emptying should be fasted before elective sedation for a minimum of 2 hours after ingesting clear liquids.³⁶ The American Academy of Pediatrics guideline on sedation follows the recommendations of the ASA for general anesthesia and advises fasting from breast milk for 4 hours and from formula, nonhuman milk, and solids for 6 hours before elective sedation.³⁶ The risks of sedation without appropriate fasting in emergent cases must be weighed against the necessity for the procedure and the expected benefit. In these cases, the lightest sedation able to achieve successful completion of the procedure should be used. Individual institutions often have specific preprocedure fasting guidelines. Prolonged fasts without fluids are more difficult for young children, so morning procedures and timely schedules are desirable.

Bowel-cleansing preparation for colonoscopy in pediatric patients should be individualized based upon the patient's age, clinical state, and anticipated willingness or ability to comply with the chosen routine. Regimens have not been standardized and vary greatly among medical centers and individual practitioners. Ingestion of clear liquids for 24 hours and a normal saline solution enema (10 mL/kg) will usually suffice for infants with normal or frequent bowel movements.³⁷ For older children, cleansing can be accomplished with intestinal lavage or dietary restrictions plus laxatives and enemas. Polyethylene glycol–electrolyte solution administered orally in a dose of 40 mL/kg/h yielded clear stool after 2.6 hours in 1 study of 20 patients³⁸; however, nausea and emesis were relatively frequent. Most pediatric patients will not ingest sufficient polyethylene glycol–electrolyte solution because of its noxious taste. The following preparations are taken from published studies of colonoscopy preparation in pediatric populations but are not inclusive of all regimens currently used:

- Senna syrup (8 mg/5 mL) 15 mL (ages 5-12 years) or 30 mL (12 years and older) in the morning and the evening on the day before the procedure, with a full liquid diet 2 days before and a clear liquid diet 1 day before procedure and 1 Fleet enema (C.B. Fleet, Lynchburg, Va) on the morning of the procedure.³⁹
- Fleet phosphosoda 22.5 mL (patient body weight <30 kg) or 45 mL (patient body weight ≥ 30 kg) in the morning and evening and a clear liquid diet on the day before the procedure.⁴⁰⁻⁴²
- Polyethylene glycol 3350 (Miralax [Schering-Plough Healthcare Products, Kenilworth, NJ], Glycolax [Schwarz Pharma, Milwaukee, Wis]) 1.5 g/kg/d for 4 days before the procedure, with clear liquid diet on day 4.⁴³

It should be noted that there are limited controlled trials of all of the currently available colonoscopy preparations in the pediatric population. In addition, sodium phosphate regimens (oral or enema) through their osmotic mechanism of action can cause potentially fatal

complications, including fluid and electrolyte shifts that lead to hypocalcemia, hyperphosphatemia, hyponatremia, nephrocalcinosis, and acute phosphate nephropathy, and should not be used in children with a history of congestive heart failure or renal disease.⁴⁴ Because of these serious potential complications, an U.S. Food and Drug Administration alert (applicable to patients of all ages) was issued in May 2006⁴⁵ and the major manufacturer of this prep (C.B. Fleet, Inc) has advised against its use as a bowel-cleansing regimen in persons younger than 18 years of age.⁴⁶ Despite this change, little data have been published that clearly demonstrate that children are more vulnerable to phosphosoda complications than adults. Preparation for nonendoscopic WCE follows the same guidelines as for adult patients: nothing by mouth for at least 8 hours before WCE performance, with or without simethicone or bowel cathartics.

American Heart Association (AHA) and ASGE guidelines for antibiotic prophylaxis for endoscopy in adults were previously published.^{47,48} More recent guidelines from the AHA, however, do not recommend antibiotic prophylaxis for bacterial endocarditis for any diagnostic or therapeutic endoscopic procedure.⁴⁹ Antibiotics should continue to be given for other indications, such as before PEG to prevent tissue infection. Guidelines for other situations, such as ventriculoperitoneal shunts, central venous lines, and the patient who is immunosuppressed, have not been developed. A survey in 2002 among 15 major pediatric gastroenterology centers revealed that the majority of centers did not administer antibiotic prophylaxis routinely for these conditions⁵⁰ and that prophylaxis practice generally followed the AHA and ASGE guidelines. In general, endocarditis prophylaxis is recommended for patients with high-risk conditions (eg, complex cyanotic congenital heart disease) undergoing high-risk procedures (eg, EGD with sclerotherapy and dilation of strictures, PEG). Routine endoscopy with or without biopsy does not warrant antibiotic prophylaxis.

Oral and nasal administration of benzodiazepines are useful for the premedication of pediatric patients before administering IV moderate sedation or anesthesia. Peak serum concentrations and central nervous system effects of midazolam are reached 10 minutes after intranasal administration and about 20 to 30 minutes after oral ingestion. In a randomized controlled trial, intranasal midazolam (0.2 mg/kg) significantly reduced negative behaviors during separation from parents but did not influence tolerance for venipuncture or EGD⁵¹ compared with intranasal saline solution. Discomfort and irritation from nasal administration largely negated the limited benefit on separation anxiety. Another placebo controlled trial evaluated oral ingestion of 0.5 mg/kg of midazolam.⁵² Oral midazolam significantly improved the ease of separation from parents and of IV insertion, the degree of amnesia for IV insertion, comfort during the procedure, and both patient and parental satisfaction scores. Physiologic

monitoring parameters were not altered before, during, or after the procedure, and there were no differences in pre-procedure time, dosages of parenteral sedatives, procedure length, postprocedure recovery, or time to discharge. Premedication with oral midazolam has also been shown to reduce the dose of propofol, allow for easier IV-line placement, ease separation from the parents, reduce pain induced by the IV-line placement, and provide greater patient comfort than a placebo.⁵³

SEDATION, ANALGESIA, AND MONITORING

Most GI endoscopy is performed by using moderate sedation⁵⁴ or general anesthesia. Moderate sedation refers to a controlled state of diminished consciousness wherein protective reflexes, the ability to respond to moderate physical or verbal stimuli, and the ability to maintain a patent airway are retained. In contrast, deep sedation refers to a controlled state of depressed consciousness from which the patient is not easily aroused, with likely loss of protective airway reflexes and of the ability to maintain a patent airway. Guidelines regarding moderate sedation and monitoring of adult⁵⁵ and pediatric³⁶ patients have been published.

Physiologic differences between pediatric and adult patients alter the risks for potentially serious complications during sedation and analgesia.⁵⁶ When ventilation is reduced by prone or supine positions, and especially by constricting garments or restraints, hypoventilation may occur.⁵⁷ Compared with adults, small and compliant pediatric airways yield significantly greater airflow resistance, which is further magnified by the addition of even modest amounts of mucous or edema. In children, the tongue fills the upper airway to a greater extent than in adults. Infants younger than 3 to 5 months old are obligate nasal breathers. Tonsils and adenoids reach maximal proportions at around ages 5 to 7 years. Hence, children are much more prone to dynamic and static episodes of airway occlusion, with or without sedation.

Hyper-reactive airways are known to occur during and for several weeks after upper-respiratory infections and have been considered a contraindication to elective procedures that require endotracheal intubation. Recent data suggest recent upper-respiratory infection is not a definite contraindication to anesthesia.⁵⁸ Extrapolation to sedation and analgesia would suggest greater caution in the setting of recent upper-respiratory infection, particularly for upper endoscopy. Finally, because of proportionally higher oxygen consumption, episodes of hypoxemia are more poorly tolerated in children than in adults. Routine oxygen administration has been advocated, because data suggest that a significant proportion of children develop oxygen desaturation during conscious sedation for endoscopy.^{57,59}

Children tend to tolerate proportional fluid excess or deficiency better than adults; however, their small size

and obligate insensible fluid losses because of thinner skin and a greater surface-to-volume ratio predispose them to dehydration, particularly with the onset of fever, diarrhea, or vomiting. The greater surface-to-volume ratio also predisposes them to more rapid heat loss and the potential for hypothermia during prolonged procedures. Although the short duration of most endoscopic procedures does not contribute greatly to dehydration or hypothermia, children should be well draped and the room temperature should be appropriately adjusted to avoid this possibility.

After early infancy, and in the absence of organ-specific pathology or dysfunction, sedative and analgesic drug effects and clearance are proportional to those seen in adults. Liver volume and proportional blood flow relative to body weight are significantly higher at birth than in adults. After early maturation of metabolic function, drug clearance is intact. Patients who are neurologically impaired, including children and adults with trisomy, can be particularly sensitive to benzodiazepines and opiate-benzodiazepine combinations.

Moderate sedation in children is most commonly performed by using midazolam, with or without fentanyl, or meperidine. As in adults, the incorporation of midazolam in sedation regimens in pediatric patients yields improved amnesia effects.⁶⁰ When fentanyl is administered, less midazolam is needed than when meperidine is given with midazolam.⁶¹ In addition, shorter recovery times occur when fentanyl is used compared with meperidine.

Administration of sedation should be weight based and titrated by response, allowing adequate time between doses to assess effects and the need for additional medication. Despite anticipated differences in sedative dosages and metabolism, requirements for individual patients may vary significantly, based, in part, on the patient's psychosocial development and attention to the surrounding environment by the endoscopy team.⁶² Not infrequently, higher doses are ultimately required in the preschool, elementary, and preteenage groups compared with teenage patients.

General anesthesia and propofol are commonly used for pediatric endoscopy, usually based upon age or anticipated patient intolerance for the procedure. Some medical centers and pediatric GI practices use general anesthesia and/or propofol exclusively for endoscopy, and this number appears to be increasing.⁶³ Other indications may include the complexity of the planned procedure, physician preferences, patient comorbidities, or institutional guidelines. One prospective evaluation noted equivalent efficacy and safety, with markedly reduced costs when using rigorously standardized procedural sedation compared with general anesthesia for performance of endoscopy in children of all age groups.⁶⁴ Higher doses of sedation were required in children 3 to 9 years of age, although deep sedation was often reached. Another randomized trial compared propofol with general anesthesia

for pediatric endoscopy and found that the use of propofol resulted in less total time for anesthesia and recovery with an equally safe profile.⁶⁵

The American Academy of Pediatrics issued recommendations regarding sedation and monitoring for diagnostic and therapeutic procedures in children.³⁶ These guidelines recommend continuous pulse oximetry and heart-rate monitoring in all levels of sedation. In addition, an individual must be specifically assigned to monitor the patient's cardiac and respiratory status. In deeply sedated patients (regardless of the intended level of sedation), this individual should have no other responsibilities (eg, assisting in the procedure) and vital signs should be recorded at least every 5 minutes. It should be noted that the training and licensure of the monitoring personnel are often dictated by individual hospital or unit policies. Most pediatric gastroenterologists are well trained and certified to provide moderate sedation, and most cases can be safely performed outside of the operating room.⁶⁶ However, because of the depth of sedation commonly required and the frequency of progression to deep sedation, personnel trained specifically in pediatric rescue maneuvers, including airway management, should be present; training in pediatric advanced life support is strongly encouraged. Because of these complexities, some centers have instituted multispecialty pediatric sedation units, wherein intensivists, specialty nurses, or anesthesiologists provide uniform and consistent sedation and monitoring.⁶⁷ Integrating capnography into monitoring protocols may improve the safety of nonintubated pediatric patients receiving moderate sedation.⁶⁸

POSTPROCEDURE MONITORING AND DISCHARGE

After completion of endoscopic procedures, children should be monitored for adverse effects of the endoscopy or sedation. Vital signs and oxygen saturation should be monitored at specific intervals. The American Academy of Pediatrics has established recommended discharge criteria after sedation.³⁶ The patient should be easily aroused, and protective reflexes should be intact. Speech and ambulation appropriate for age should return to pre-sedation levels. Patients who received reversal agents (eg, flumazenil or naloxone) may require longer periods of observation, because the half-life of the offending agent may exceed that of the reversal medication and lead to re-sedation.

Before discharge, specific written and verbal instructions and information should be given to a parent, legal guardian, or other responsible adult. This should include signs and symptoms of potential adverse outcomes and complications, steps to follow in the event of a complication, and a telephone number where 24-hour coverage is available in the event of an emergency. Special instructions

to observe the child's head position to prevent airway occlusion should be given in cases where the child will travel in a car seat. In such cases, it may be preferable to have more than 1 adult accompany the child on the day of the procedure.

EQUIPMENT

Resuscitative equipment should mirror that available for adult conscious sedation, with attention to the availability of devices of appropriate size and drug doses for all sizes and ages being treated. Necessary supplies include pediatric-caliber IV tubing, arm boards, IV needles, face masks, oral and nasal airways, laryngoscopes, suction catheters, endotracheal tubes, and nasogastric tubes. An emergency or code cart stocked for representative age groups should be readily available.

Diameters of both adult and pediatric endoscopes are rapidly evolving. Reduced-caliber instruments are available for procedures in infants, younger children, and non-sedated adults. Pediatric-caliber biopsy forceps are designed for use through smaller endoscopes. Their reduced bite is also appropriate for the thinner small bowel and colonic mucosa of infants and young children. Standard adult gastroscopes are generally safe in children who weigh more than 25 kg.⁶⁹ Smaller-diameter (5-8 mm) instruments may be more appropriate for gastroscopy in smaller children and infants. For colonoscopy, adult colonoscopes (11.7- to 13-mm diameter) are acceptable in teenage patients approaching adult size. Smaller, more flexible colonoscopes (<11.7-mm diameter) are suitable for most average-size preschool and elementary-school aged children.⁷⁰ Smaller neonatal endoscopes or standard upper endoscopes can be used for colonoscopy in infants and toddlers. Some upper endoscopes may be stiffer than colonoscopes, however, so care should be taken to avoid excessive stretching of the splenic and hepatic flexures. When endoscopic injection agents are used, the volume should be based upon body size, because there is the potential for increased local and systemic effects on the basis of smaller body size. Unfortunately, no data are available regarding such effects. Devices such as percutaneous gastrostomy tubes should be appropriately sized, depending on the patient's needs and body size.

The use of double-balloon enteroscopy (DBE) has not been described specifically in pediatric populations, though series of DBE in patients with obscure GI bleeding contain pediatric patients as young as 9 years of age.^{71,72}

SUMMARY

- Endoscopic procedures including ERCP, EUS, WCE, and DBE in the pediatric population are both safe and effective. (1C+)

- Endoscopy in children should be performed by pediatric-trained gastroenterologists whenever possible. (3)
- Adult-trained endoscopists are often needed to provide advanced endoscopic services, such as EUS and ERCP, or basic endoscopy services in the absence of pediatric-trained endoscopists, and should coordinate their services with pediatricians and pediatric specialists. (3)
- Endoscopy should be performed in symptomatic pediatric patients with known or suspected ingestion of caustic substances and should be considered even in the absence of symptoms. (1C)
- Procedural and resuscitative equipment of a size and type appropriate for pediatric use should be readily available during endoscopic procedures. (3)
- Preprocedural preparation should be individualized according to the patient's age, size, clinical state, and planned procedure. (1C)
- Preprocedural fasting from milk and solids vary by institutional requirements but a minimum fasting from all oral intake (including clear liquids) of 2 hours is recommended. (3)
- Indications for antibiotic prophylaxis in children mirror that for adults. (3)
- General anesthesia is commonly used for pediatric endoscopy. (1C)
- All sedated pediatric patients should receive routine oxygen administration and should be monitored with a minimum of pulse oximetry and heart-rate monitoring. (3)
- In deeply sedated patients, 1 individual having no other responsibilities should be assigned to monitor the patient's cardiac and respiratory status and to record vital signs. (3)
- The presence of personnel trained specifically in pediatric life support and airway management during procedures requiring sedation is strongly recommended. (3)

Abbreviations: AHA, American Heart Association; ASA, American Society of Anesthesiologists; ASGE, American Society for Gastrointestinal Endoscopy; DBE, double-balloon enteroscopy; IV, intravenous; WCE, wireless capsule endoscopy.

REFERENCES

1. Hassall E. NASPGN position paper: requirements for training to ensure competence of endoscopists performing invasive procedures in children. *J Pediatr Gastroenterol Nutr* 1997;24:345-7.
2. Squires RH, Colletti RB. Indications for pediatric gastrointestinal endoscopy: a medical position statement of the North American Society of Pediatric Gastroenterology and Nutrition. *J Pediatr Gastroenterol Nutr* 1996;23:107-10.
3. Lee KK. Endoscopy. In: Osborn LM, DeWitt TG, First LR, et al, editors. *Pediatrics*. Philadelphia: Elsevier Mosby; 2005. p. 1750-6.
4. Eisen GM, Baron TH, Dominitz JA, et al. American Society for Gastrointestinal Endoscopy. Guideline for the management of ingested foreign bodies. *Gastrointest Endosc* 2002;55:802-6.
5. Wilsey MJ Jr, Scheimann AO, Gilger MA. The role of upper gastrointestinal endoscopy in the diagnosis and treatment of caustic ingestion, esophageal strictures, and achalasia in children. *Gastrointest Endosc Clin N Am* 2001;11:767-87, vii-viii.
6. Lamireau T, Rebouissoux L, Denis D, et al. Accidental caustic ingestion in children: is endoscopy always mandatory? *J Pediatr Gastroenterol Nutr* 2001;33:81-4.
7. Gupta SK, Croffie JM, Fitzgerald JF. Is esophagogastroduodenoscopy necessary in all caustic ingestions? *J Pediatr Gastroenterol Nutr* 2001;32:50-3.
8. Poley JW, Steyerberg EW, Kuipers EJ, et al. Ingestion of acid and alkaline agents: outcome and prognostic value of early upper endoscopy. *Gastrointest Endosc* 2004;60:372-7.
9. Baskin D, Urganci N, Abbasoglu L, et al. A standardised protocol for the acute management of corrosive ingestion in children. *Pediatr Surg Int* 2004;20:824-8.
10. Tiryaki T, Livanelioglu Z, Atayurt H. Early bougienage for relief of stricture formation following caustic esophageal burns. *Pediatr Surg Int* 2005;21:78-80.
11. Sonneberg A, Lieberman DA. Calculating the benefit of a negative endoscopy. *Gastrointest Endosc* 2003;58:752-4.
12. Samer Ammar M, Pfefferkorn MD, Croffie JM, et al. Complications after outpatient upper GI endoscopy in children: 30-day follow-up. *Am J Gastroenterol* 2003;98:1508-11.
13. Hyer W, Beveridge I, Domizio P, et al. Clinical management and genetics of gastrointestinal polyps in children. *J Pediatr Gastroenterol Nutr* 2000;31:469-79.
14. Romero R, Abramowsky CR, Pillen T, et al. Peripheral eosinophilia and eosinophilic gastroenteritis after pediatric liver transplantation. *Pediatr Transplant* 2003;7:484-8.
15. Sigurdsson L, Reyes J, Todo S, et al. Anatomic variability of rejection in intestinal allografts after pediatric intestinal transplantation. *J Pediatr Gastroenterol Nutr* 1998;27:403-6.
16. Kori M, Gladish V, Ziv-Sokolovskaya N, et al. The significance of routine duodenal biopsies in pediatric patients undergoing upper intestinal endoscopy. *J Clin Gastroenterol* 2003;37:39-41.
17. Fox VL, Werlin SL, Heyman MB. Endoscopic retrograde cholangiopancreatography in children. Subcommittee on Endoscopy and Procedures of the Patient Care Committee of the North American Society for Pediatric Gastroenterology and Nutrition. *J Pediatr Gastroenterol Nutr* 2000;30:335-42.
18. Varadarajulu S, Wilcox CM, Hawes RH, et al. Technical outcomes and complications of ERCP in children. *Gastrointest Endosc* 2004;60:367-71.
19. Cheng CL, Fogel EL, Sherman S, et al. Diagnostic and therapeutic endoscopic retrograde cholangiopancreatography in children: a large series report. *J Pediatr Gastroenterol Nutr* 2005;41:445-53.
20. Issa H, Al-Haddad A, Al-Salem AH. Diagnostic and therapeutic ERCP in the pediatric age group. *Pediatr Surg Int* 2007;23:111-6.
21. Roseau G, Palazzo L, Dumontier I, et al. Endoscopic ultrasonography in the evaluation of pediatric digestive diseases: preliminary results. *Endoscopy* 1998;30:477-81.
22. Fox VL, Nurko S, Teitelbaum JE, et al. High-resolution EUS in children with eosinophilic "allergic" esophagitis. *Gastrointest Endosc* 2003;57:30-6.
23. Varadarajulu S, Wilcox CM, Eloubeidi MA. Impact of EUS in the evaluation of pancreaticobiliary disorders in children. *Gastrointest Endosc* 2005;62:239-44.
24. Usui N, Kamata S, Kawahara H, et al. Usefulness of endoscopic ultrasonography in the diagnosis of congenital esophageal stenosis. *J Pediatr Surg* 2002;37:1744-6.
25. Faigel DO, Burke A, Ginsberg GG, et al. The role of endoscopic ultrasound in the evaluation and management of foregut duplications. *Gastrointest Endosc* 1997;45:99-103.
26. Emblem R, Morkrid L, Bjornland K. Anal endosonography is useful for postoperative assessment of anorectal malformations. *J Pediatr Surg* 2007;42:1549-54.

27. Guilhon de Araujo Sant'Anna AM, Dubois J, Miron MC, et al. Wireless capsule endoscopy for obscure small-bowel disorders: final results of the first pediatric controlled trial. *Clin Gastroenterol Hepatol* 2005;3:264-70.
28. Barth BA, Donovan K, Fox VL. Endoscopic placement of the capsule endoscope in children. *Gastrointest Endosc* 2004;60:818-21.
29. Shamir R, Hino B, Hartman C, et al. Wireless video capsule in pediatric patients with functional abdominal pain. *J Pediatr Gastroenterol Nutr* 2007;44:45-50.
30. Thomson M, Fritscher-Ravens A, Mylonaki M, et al. Wireless capsule endoscopy in children: a study to assess diagnostic yield in small bowel disease in paediatric patients. *J Pediatr Gastroenterol Nutr* 2007;44:192-7.
31. Ginsberg GG, Barkun AN, Bosco JJ, et al. Wireless capsule endoscopy. *Wireless capsule endoscopy: August 2002* 2002;56:621-4.
32. Arguelles-Arias F, Caunedo A, Romero J, et al. The value of capsule endoscopy in pediatric patients with a suspicion of Crohn's disease. *Endoscopy* 2004;36:869-73.
33. Hoffman GM, Nowakowski R, Troshynski TJ, et al. Risk reduction in pediatric procedural sedation by application of an American Academy of Pediatrics/American Society of Anesthesiologists process model. *Pediatrics* 2002;109:236-43.
34. American Society for Gastrointestinal Endoscopy. Informed consent for gastrointestinal endoscopy. *Gastrointest Endosc* 2007;66:213-8.
35. Mahajan L, Wyllie R, Steffen R, et al. The effects of a psychological preparation on anxiety in children and adolescents undergoing gastrointestinal endoscopy. *J Pediatr Gastroenterol Nutr* 1998;27:161-5.
36. American Academy of Pediatrics, American Academy of Pediatric Dentistry, Coté CJ, et al. Guidelines for monitoring and management of pediatric patients during and after sedation for diagnostic and therapeutic procedures: an update. *Pediatrics* 2006;118:2587-602.
37. Fox VL. Lower gastrointestinal endoscopy. In: Walker WA, Durie PR, Hamilton JR, et al, editors. *Pediatric gastrointestinal disease*. Hamilton (ON), Canada: BC Decker; 2000. p. 1415.
38. Sondheimer JM, Sokol RJ, Taylor SF, et al. Safety, efficacy, and tolerance of intestinal lavage in pediatric patients undergoing diagnostic colonoscopy. *J Pediatr* 1991;119:148-52.
39. Trautwein AL, Vinitski LA, Peck SN. Bowel preparation before colonoscopy in the pediatric patient: a randomized study. *Gastroenterol Nurs* 1996;19:137-9.
40. da Silva MM, Briars GL, Patrick MK, et al. Colonoscopy preparation in children: safety, efficacy, and tolerance of high- versus low-volume cleansing methods. *J Pediatr Gastroenterol Nutr* 1997;24:33-7.
41. El-Baba MF, Padilla M, Houston C, et al. A prospective study comparing oral sodium phosphate solution to a bowel cleansing preparation with nutrition food package in children. *J Pediatr Gastroenterol Nutr* 2006;42:174-7.
42. Gremse DA, Sacks AI, Raines S. Comparison of oral sodium phosphate to polyethylene glycol-based solution for bowel preparation for colonoscopy in children. *J Pediatr Gastroenterol Nutr* 1996;23:586-90.
43. Pashankar DS, Uc A, Bishop WP. Polyethylene glycol 3350 without electrolytes: a new safe, effective, and palatable bowel preparation for colonoscopy in children. *J Pediatr* 2004;144:358-62.
44. Wexner SD, Beck DE, Baron TH, et al. American Society of Colon and Rectal Surgeons. A consensus document on bowel preparation before colonoscopy: prepared by a Task Force from the American Society of Colon and Rectal Surgeons (ASCRS), the American Society for Gastrointestinal Endoscopy (ASGE), and the Society of American Gastrointestinal and Endoscopic Surgeons (SAGES). *Gastrointest Endosc* 2006;63:894-909.
45. U.S. Food and Drug Administration. Oral sodium phosphate products for bowel cleansing. Available at: http://www.fda.gov/cder/drug/InfoSheets/HCP/OSP_solutionHCP.pdf. Accessed August 15, 2007.
46. C.B. Fleet Company, Inc. Key facts about the safe use of Fleet Phospho-soda (sodium phosphates oral solution). Available at: <http://www.phospho-soda.com/professionals/pdf/KeyFacts.pdf>. Accessed August 15, 2007.
47. Dajani AS, Taubert KA, Wilson W, et al. Prevention of bacterial endocarditis. Recommendations by the American Heart Association. *JAMA* 1997;277:1794-801.
48. Hirota WK, Petersen K, Baron TH, et al. Guidelines for antibiotic prophylaxis for GI endoscopy. *Gastrointest Endosc* 2003;58:475-82.
49. Wilson W, Taubert KA, Gewitz M, et al. Prevention of Infective Endocarditis. Guidelines From the American Heart Association. A Guideline From the American Heart Association Rheumatic Fever, Endocarditis, and Kawasaki Disease Committee, Council on Cardiovascular Disease in the Young, and the Council on Clinical Cardiology, Council on Cardiovascular Surgery and Anesthesia, and the Quality of Care and Outcomes Research Interdisciplinary Working Group. *Circulation* 2007;116:1736-54.
50. Snyder J, Bratton B. Antimicrobial prophylaxis for gastrointestinal procedures: current practices in North American academic pediatric programs. *J Pediatr Gastroenterol Nutr* 2002;35:564-9.
51. Fishbein M, Lugo RA, Woddlund J, et al. Evaluation of intranasal midazolam in children undergoing esophago-gastroduodenoscopy. *J Pediatr Gastroenterol Nutr* 1997;25:261-6.
52. Liacouras CA, Mascarenhas M, Poon C, et al. Placebo-controlled trial assessing the use of oral midazolam as a premedication to conscious sedation for pediatric endoscopy. *Gastrointest Endosc* 1998;47:455-60.
53. Paspatis GA, Charoniti I, Manolaraki M, et al. Synergistic sedation with oral midazolam as a premedication and intravenous propofol versus intravenous propofol alone in upper gastrointestinal endoscopies in children: a prospective, randomized study. *J Pediatr Gastroenterol Nutr* 2006;43:195-9.
54. Mamula P, Markowitz JE, Neiswender K, et al. Safety of intravenous midazolam and fentanyl for pediatric GI endoscopy: prospective study of 1578 endoscopies. *Gastrointest Endosc* 2007;65:203-10.
55. Waring JP, Baron TH, Hirota WK, et al. Guidelines for conscious sedation and monitoring during gastrointestinal endoscopy. *Gastrointest Endosc* 2003;58:317-22.
56. Tolia V, Brennan S, Aravind MK, et al. Pharmacokinetic and pharmacodynamic study of midazolam in children during esophagogastroduodenoscopy. *J Pediatr* 1991;119:467-71.
57. Thakkar K, El-Serag H, Mattek N, et al. Complications of pediatric EGD: a 4-year experience in PEDS-CORI. *Gastrointest Endosc* 2007;65:213-21.
58. Tait AR, Malviya S. Anesthesia for the child with an upper respiratory tract infection: still a dilemma? *Anesth Analg* 2005;100:59-65.
59. Gilger MA, Jeiven SD, Barrish JO, et al. Oxygen desaturation and cardiac arrhythmias in children during esophagogastroduodenoscopy using conscious sedation. *Gastrointest Endosc* 1993;39:392-5.
60. Bahal-O'Mara N, Nahata MC, Murray RD, et al. Sedation with meperidine and midazolam in pediatric patients undergoing endoscopy. *Eur J Clin Pharmacol* 1994;47:319-23.
61. Chuang E, Wenner WJ, Piccoli DA, et al. Intravenous sedation in pediatric upper gastrointestinal endoscopy. *Gastrointest Endosc* 1995;42:156-60.
62. Gilger MA. Conscious sedation for endoscopy in the pediatric patient. *Gastroenterol Nurs* 1993;16:75-9.
63. Koh JL, Black DD, Leatherman IK, et al. Experience with an anesthesiologist interventional model for endoscopy in a pediatric hospital. *J Pediatr Gastroenterol Nutr* 2001;33:314-8.
64. Squires RH, Morriss F, Schluterman S, et al. Efficacy, safety, and cost of intravenous sedation versus general anesthesia in children undergoing endoscopic procedures. *Gastrointest Endosc* 1995;41:99-104.
65. Kaddu R, Bhattacharya D, Metriyakool K, et al. Propofol compared with general anesthesia for pediatric GI endoscopy: is propofol better? *Gastrointest Endosc* 2002;55:27-32.

66. Wengrower D, Gozal D, Gozal Y, et al. Complicated endoscopic pediatric procedures using deep sedation and general anesthesia are safe in the endoscopy suite. *Scand J Gastroenterol* 2004;39:283-6.

67. Lowrie L, Weiss AH, Lacombe C. The pediatric sedation unit: a mechanism for pediatric sedation. *Pediatrics* 1998;102:1-9.

68. Lightdale JR, Goldmann DA, Feldman HA, et al. Microstream capnography improves patient monitoring during moderate sedation: a randomized, controlled trial. *Pediatrics* 2006;117:e1170-8.

69. Benaroch LM, Rudolph CD. Introduction to pediatric esophagogastro-duodenoscopy and enteroscopy. *Gastrointest Endosc Clin N Am* 1994;4:121-42.

70. Wyllie R, Kay MH. Colonoscopy and therapeutic intervention in infants and children. *Gastrointest Endosc Clin N Am* 1994;4:143-60.

71. Sun B, Rajan E, Cheng S, et al. Diagnostic yield and therapeutic impact of double-balloon enteroscopy in a large cohort of patients with obscure gastrointestinal bleeding. *Am J Gastroenterol* 2006;101:2011-5.

72. Manabe N, Tanaka S, Fukumoto A, et al. Double-balloon enteroscopy in patients with GI bleeding of obscure origin. *Gastrointest Endosc* 2006;64:135-40.

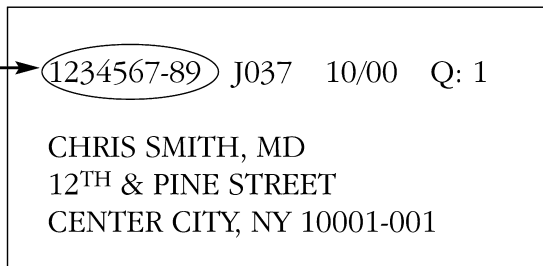
Prepared by:
 ASGE STANDARDS OF PRACTICE COMMITTEE
 Kenneth K. Lee, MD, NASPGHAN Representative
 Michelle A. Anderson, MD
 Todd H. Baron, MD, Chair
 Subhas Banerjee, MD
 Brooks D. Cash, MD
 Jason A. Dominitz, MD, MHS
 Seng-lan Gan, MD
 M. Edwyn Harrison, MD
 Steven O. Ikenberry, MD
 Sanjay B. Jagannath, MD
 David Lichtenstein, MD
 Bo Shen, MD
 Robert D. Fanelli, MD, SAGES Representative
 Trina Van Guilder, RN, SGNA Representative
 This document is a product of the ASGE Standards of Practice Committee.
 This document was reviewed and approved by the governing board of the ASGE.

Access to ***Gastrointestinal Endoscopy Online*** is reserved for all subscribers!

Full-text access to ***Gastrointestinal Endoscopy Online*** is available for all subscribers. ASGE MEMBER SUBSCRIBERS: To activate your individual online subscription, please visit <http://www.asge.org> and follow the instructions. NON-MEMBER SUBSCRIBERS: To activate your individual online subscription, please visit <http://www.giejournal.org> and follow the prompts to activate your *online access*. To activate your account, you will need your subscriber account/membership number, which you can find on your mailing label (*note*: the number of digits in your subscriber account number varies from 6 to 10 digits). See the example below in which the subscriber account number has been circled:

Sample mailing label

This is your Nonmember subscriber account number →



Personal subscriptions to ***Gastrointestinal Endoscopy Online*** are for individual use only and may not be transferred. Use of ***Gastrointestinal Endoscopy Online*** is subject to agreement to the terms and conditions as indicated online.